



Improvement in postural orthostatic tachycardia syndrome in a patient with multiple concussions and post-concussion syndrome



David Schiller, DC, DACNB, FABBIR, CCSP, FIAMA
Private practice, Avon, CT, USA

INTRODUCTION

A 19-year-old male with a history of eight concussions between September 2009 and March 2015 presented for evaluation with symptoms of fatigue, headaches, and the inability to sustain attention and focus which the patient described as “head fatigue.” He described his vision as being “sub-par” and that he also experienced tinnitus. Injuries were sustained playing football and basketball in which he hit his head on the field and court. While playing baseball he was hit in the head by a pitch and sustained another head injury while sliding into base. Other concussions were sustained when accidentally getting “elbowed” by a friend and “table-topped” during a prank. He had also hit his head on weights while working out. The post-concussion syndrome symptoms now interfere with schoolwork and other cognitive tasks to the point where he delayed entering college because of the amount of time that was missed during his high school years. The patient was observed to be searching for words. The patient also described digestive disturbances which have caused an inability to tolerate certain foods. Post-concussion syndrome was diagnosed at a local sports medicine clinic and children’s hospital.

METHODS

Neurological examination revealed dysautonomia, specifically postural orthostatic tachycardia syndrome (POTS), with a rise in heart rate from 76 to 106 bpm using a pulse oximeter.

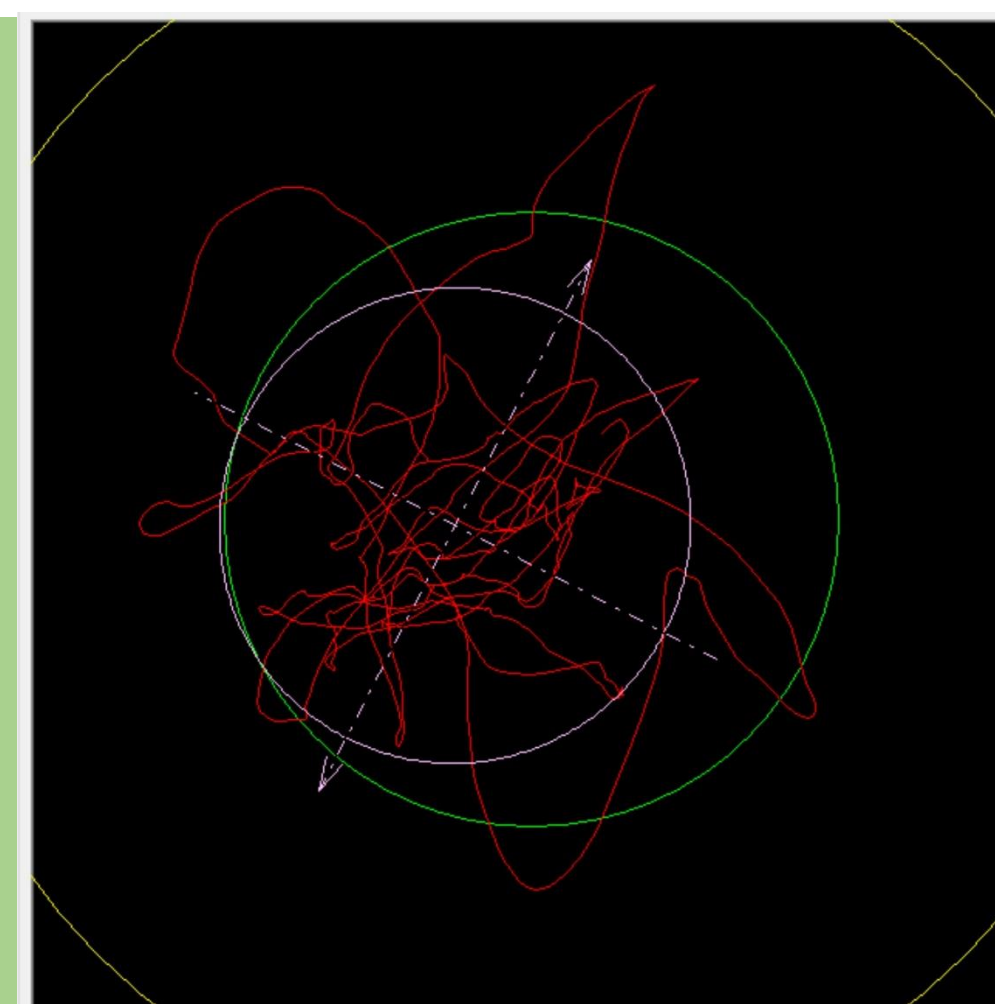
Position	Heart Rate	Blood Pressure
Supine	76 bpm	131/72
Standing	106 bpm	130/71

Orthostatic testing revealed no rise in blood pressure. Exam revealed: light sensitivity in the right eye with facial muscle activation during pupillary testing, intention tremor during finger-to-nose assessment on the left, and aberrant optokinetic responses (OPK) to the right. Evaluation of pursuits revealed saccadic intrusions. Testing of the vestibuloocular reflex (VOR) was not tolerated and caused immediate symptoms described as “head fatigue” and headache. Computerized Dynamic Posturography (CDP) revealed aberrant patterns during testing with eyes closed on a perturbed surface with the head turned to the left.

Initial computerized posturography

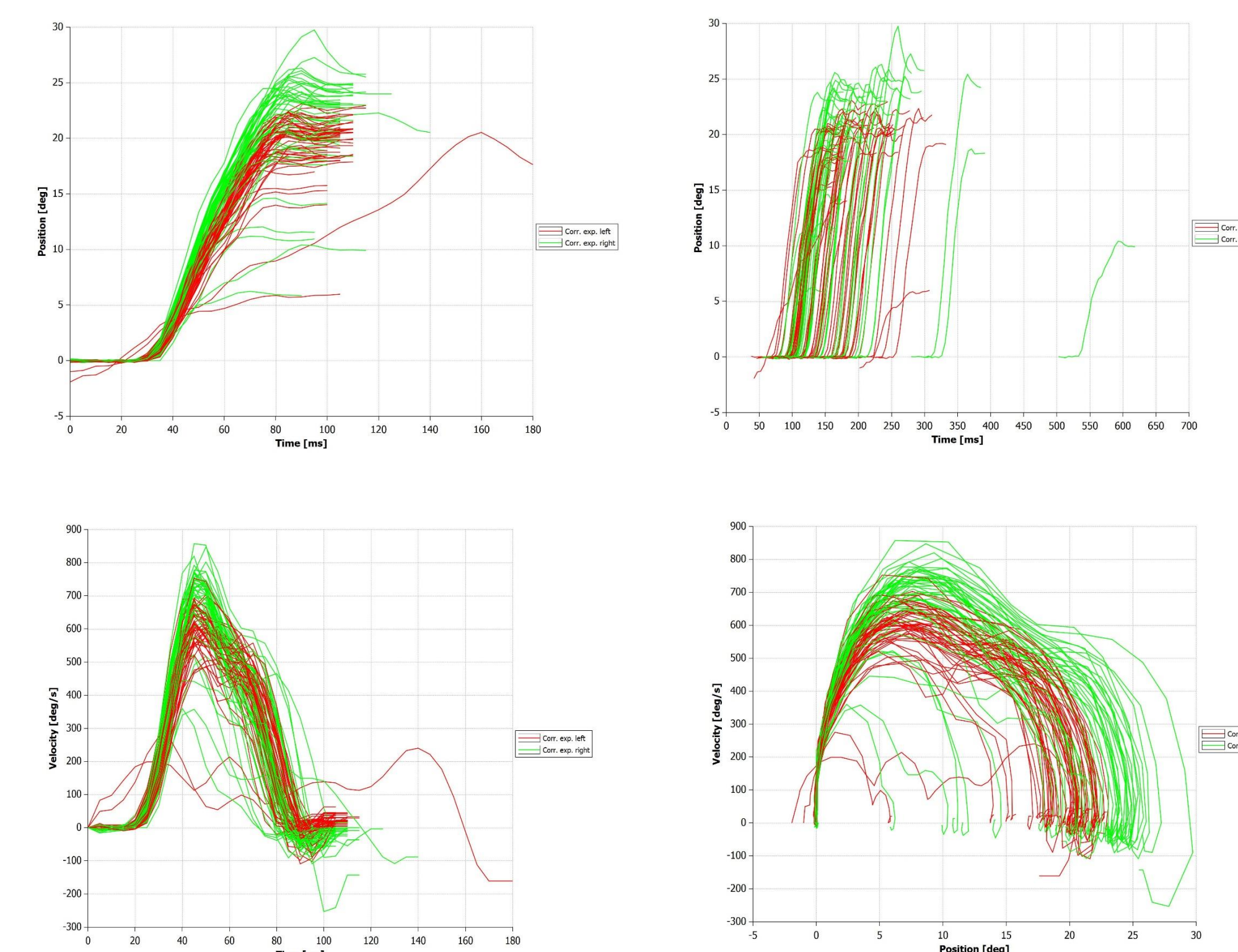
Initial Acquisition

Eyes closed, perturbed surface head turned left. Ellipse: sway anterior to right and posterior to left. This is considered paradoxical



METHODS

The patient participated in a multimodal neurorehabilitation program that included specific eye movements for two weeks. It included pursuits and combinations of saccades and pursuits that were developed from the exam findings and the following saccodometer readings:



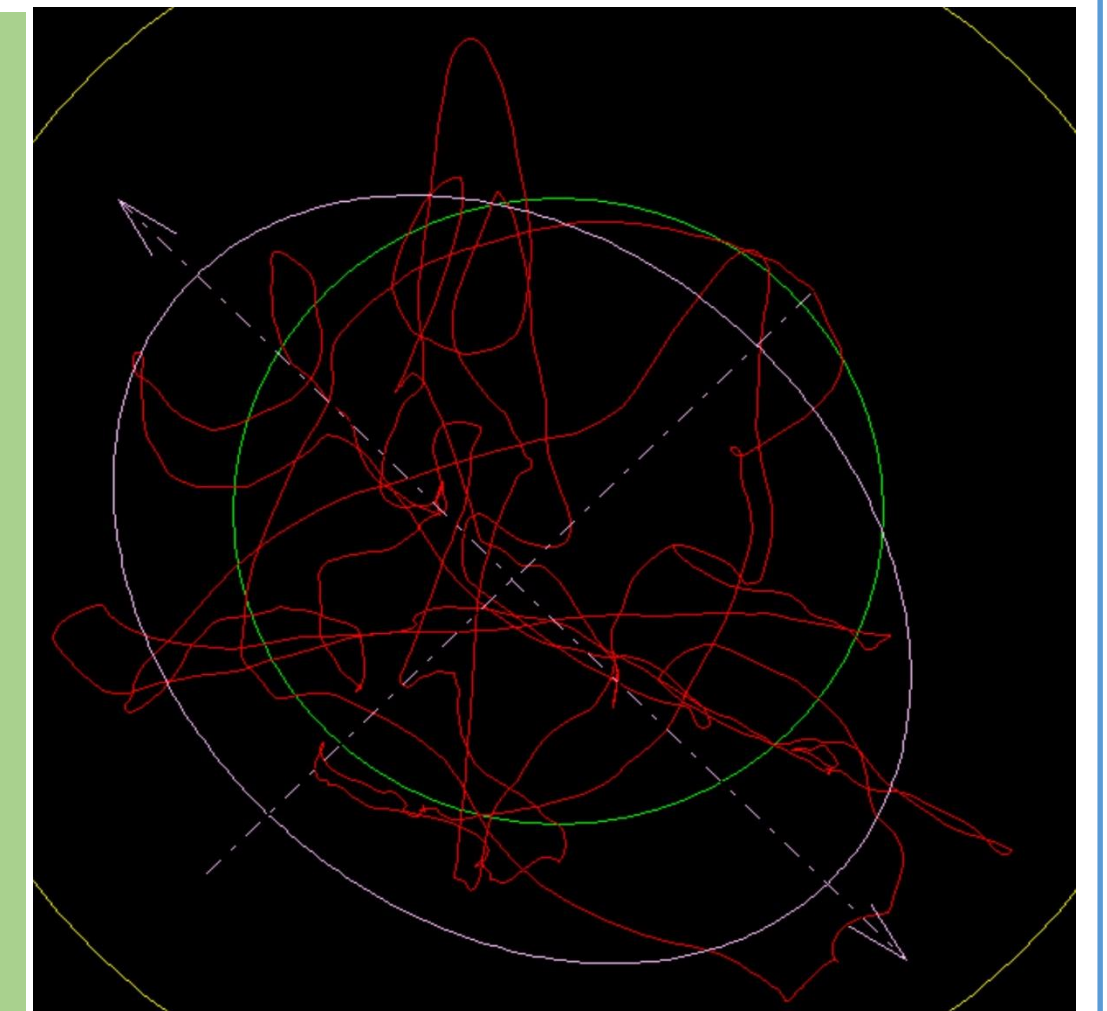
Eye movement exercises started with sinusoidal pursuits in the supine position and progressed into seated and then standing positions while monitoring heart rate and other signs of metabolic capacity to address the dysautonomia. Combinations of saccades and pursuits were prescribed as the patient could tolerate more demanding tasks without exceeding metabolic capacity. Gaze stabilization exercises were not prescribed because the patient could not tolerate head movement as demonstrated during testing of the VOR.

RESULTS

Post computerized posturography

Post Acquisition

Eyes closed, perturbed surface, head turned left: Ellipse: sway anterior to the left and posterior to the right. The initial assessment normalized



The POTS signs improved during the treatment period with a change in heart rate from supine to standing of 10 bpm versus the original rise of 30 bpm. The patient reported a reduction in severity of headaches. Resting heart rate in the supine position reduced consistently to the mid to upper 60s (bpm). The aberrant OPK and pursuits improved with reduction in saccadic intrusions. The patient was also able to tolerate some head movement with no symptoms produced.

CONCLUSIONS

This author recommends further investigation into the treatment of POTS and post-concussion syndrome with multimodal neurorehabilitation techniques that include specific eye movement combinations.

For more information contact:

David Schiller, DC, DACNB, FABBIR, CCSP, FIAMA
25 Bailey Road, Avon, CT, USA
drschiiller@comcast.net
www.DrDavidSchiller.com